Sub-millimeter Voxel Diffusion Tensor Imaging of the Optic Chiasm

Joelle Sarlls, Carlo Pierpaoli
National Institutes of Health, Bethesda, MD, United States

Introduction: Diffusion tensor MRI (DTI) has become a powerful tool for the investigation into tissue architecture and integrity. However, there are numerous anatomical details in the brain that are undetectable at typical DTI image resolution, being 8mm3 voxels, due to partial volume effects and the sequence used in the majority of DTI studies, single-shot EPI, is sensitive to magnetic field inhomogeneity near air/tissue interfaces. Recently, we developed a radial fast spin-echo (FSE) sequence for high-resolution DTI of *in vivo* brain that allows sub-millimeter isotropic voxels to be acquired in areas of magnetic field inhomogeneity [1], like the optic nerve/chiasm.

Methods: A diffusion-weighted radial-FSE sequence consisting of a Stejskal-Tanner diffusion preparation period followed by a train of 180° RF refocusing pulses with a mixed-CPMG phase cycling scheme [2] and a 300% wider refocusing than excitation slice, to improve B1-homogeneity [3], was used to collect data on a 3T GE scanner. DTI data sets were acquired in an oblique plane aligned to the angle of the optic nerve/chiasm and contained a single non-diffusion-weighted image along with b-value=1000 s/mm2 images in six non-collinear diffusion directions. Data was acquired of a healthy male volunteer at 0.8mm isotropic resolution (scan parameters: TE/TR = 68/2000ms, ETL = 4, and 512 radial lines). Data was also acquired of a second healthy male volunteer at 0.9mm isotropic resolution (scan parameters: TE/TR =68/2500ms, ETL = 4, and 512 radial lines). In addition, a T1-FLAIR image of the same oblique slice was acquired at an equal 0.9mm isotropic resolution.

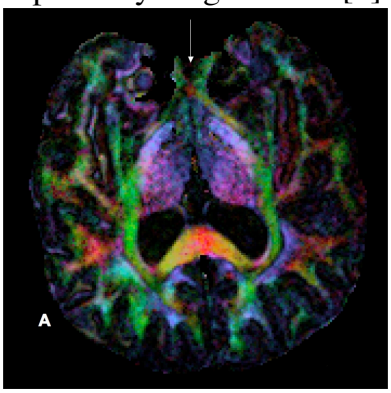

Results: Directionally encoded color (DEC) maps [4] calculated from the acquired DTI data sets with 0.8 and 0.9mm isotropic voxels are shown in **A** and **B**, respectively. Due to the ability to collect DTI data at sub-millimeter resolutions, partial volume effects are dramatically reduced and anatomical details, even within fiber tracts, can be revealed. White matter tracts running in the R/L direction are red, A/P direction are green, and the S/I direction are blue. In each image the white arrow points to the optic chiasm. The decussation of the fibers in the medial portion of the optic chiasm can be clearly seen in **A** as the red area in the middle of the chiasm, while the lateral fibers of the optic chiasm that don't cross can be seen in green continuing their antero-posterior trajectory and entering the ipsilateral optic tract. Due to the high-resolution obtained in **B**, several different bundles of fibers can be distinguished in white matter that appear homogeneous in **C,** the corresponding T1-FLAIR image. Also, in subcortical areas very thin branches of U-fibers (red) can be detected.

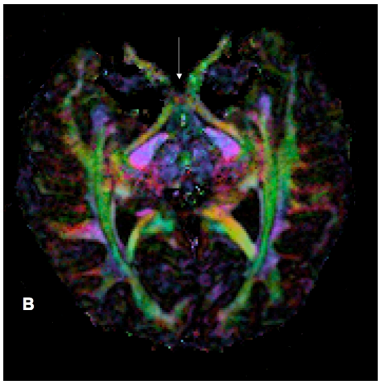

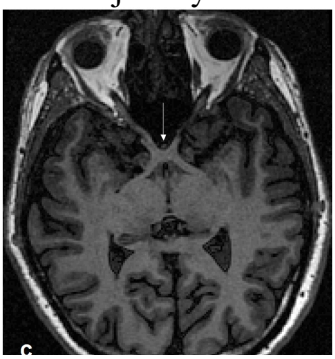

Conclusions: Using the modified radial-FSE sequence at 3T, images can be produced with a voxel size about 10 times smaller than that currently achievable with EPI-based DTI. This allows anatomical details in the brain to be studied with DTI, regarless of

proximity to air/tissue interfaces. The DTI data sets in this work
reveal fine details, even within fiber tracts, like the medial decussation in the optic chiasm.

References: [1] Sarlls *et. al.,* ISMRM, 15: 1491, 2007. [2] Pipe *et. al.,* MRM, 47: 42-52, 2002. [3] Pell *et. al.*, JMRI, 23: 248-252, 2006. [4] Pajevic *et. al.,* MRM, 42: 526-540, 1999.

Category = Imaging Techniques and Contrast Mechanism
Subcategory = Diffusion MRI
Accept Oral = Yes