Diffusion Tensor MR Microscopy of Adult Zebrafish.

R. Z. Freidlin[1], H. D. Morris[2], F. Horkay[3], C. Pierpaoli[3], R. Toyama[3], I. B. Dawid[3], P. J. Basser[3]

[1]CIT, National Institutes of Health, Bethesda, Maryland, United States, [2]NINDS, National Institutes of Health, Bethesda, Maryland, United States, [3]NICHD, National Institutes of Health, Bethesda, Maryland, United States

INTRODUCTION

To study gene expression and control, various knockout and knockin animal models have been developed. Through mutagenic screening, the function of such genes can sometimes be inferred. Numerous zebrafish mutant phenotypes have received attention recently because they lead to pathologies exhibited in humans. Presently, *in vivo* and *in vitro* fluorescent confocal microscopy [1] is the primary method by which gene expression is studied in zebrafish. Owing to its increasing thickness and optical turbity with age, this technique can only be used to study genes expressed during early embryonic development. *In vivo* and *in vitro* MR Microscopy may overcome this limitation since it is amenable to studying optically opaque, thick adult zebrafish specimen. To date, there have been no DT-MRM studies performed on zebrafish.

METHODS

Diffusion Weighted (DW) images of an adult zebrafish were performed on a 7T Vertical Bruker (Billerica, MA) Oxford Instruments 81 mm Microimaging MRI System equipped with a Micro2.5 microscopy probe (15mm solenoid coil) with 950 mT/m 3-axis gradients. Samples were positioned in a custom-made holder in a 15mm glass tube filled with MR-compatible perfluoropolyether oil ("Fomblin"). DWIs were obtained using a PGSE DWI sequence with δ (pulse duration) = 1.5 ms, Δ (diffusion time) = 9ms, TR = 2000 ms, and TE = 17.1 ms. Other imaging parameters were: in-plane resolution 117x117μm^2, slice thickness = 1mm, number of averages: n = 2. Thirty-two DWIs per slice were acquired during 8 hours of scanning. Thirty-one of these were attenuated by diffusion gradients $\mathbf{G}=(G_x, G_y, G_z)$ and one was not attenuated (**G=0**). In each direction the maximum diffusion gradient strength was set to 94.5 G/cm. At each voxel location in the raw image, the apparent diffusion tensor, ***D***, was calculated [2]. Tensor-derived parameters, such as the Trace, fractional anisotropy, principal directions and principal diffusivities were all calculated and plotted.

RESULTS and DISCUSSION

Figure 1. shows (a) the T2-weighted amplitude image and (b) the orientationally-averaged mean diffusivity map (<***D***>=Trace/3). The amplitude image is surprisingly featureless, showing uniform intensity throughout the muscle-filled regions. The <***D***> map shows somewhat more delineation between different muscle groups that are consistent with a histological slice (Fig. 1c) of a 5 days old zebrafish larva. Also, regions appearing bright in the amplitude image appear dark in the <***D***> because average mean diffusivity values reveal well-organized bundles of fiber in these areas that have different T2 relaxation constants. Figure 2 (a) is the direction-encoded color map [3] and 2 (b) is the vector field direction map showing the projection of the principal direction in the plane of the image. The bluish color in the muscle groups indicates that fibers there are pointing into the page (see legend in Fig. 2c), consistent with their known anatomy. Muscle fiber groups are also easily discernible in this image. Moreover, the spinal cord is clearly visible along the central line. Also noteworthy are radially oriented structures near the skin in Figs. 2 (a) and (b).

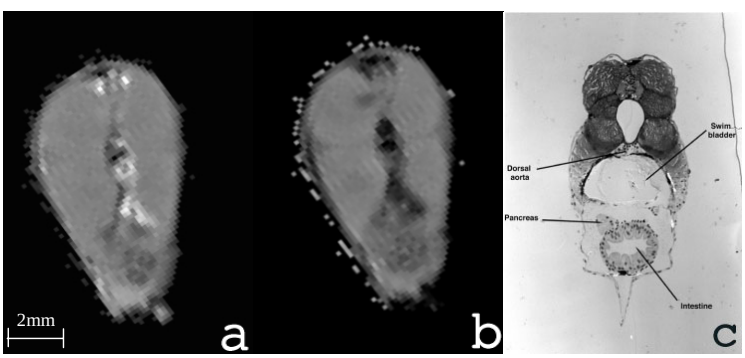

Fig. 1. (a) T2- weighted amplitude image, (b) apparent mean diffusivity, (c) histological slice of a 5 days old zebrafish larva.

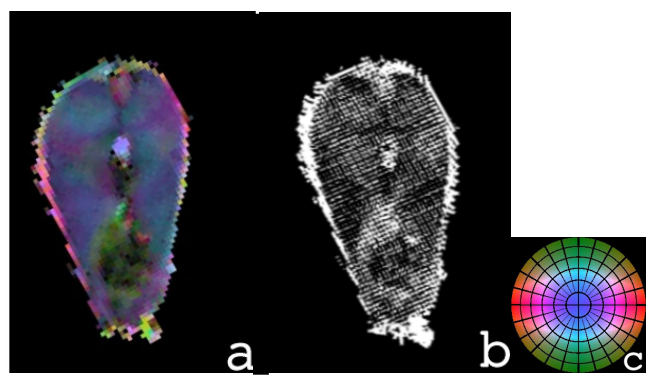

Fig. 2. (a) color map, (b) line field map, (c) color map legend: red – left to right direction, green – up and down direction, blue – through the plane.

CONCLUSION

This pilot study shows the potential of *in vitro* DT-MRM to study different muscle and nerve tissues in a normal adult zebrafish. Future work will involve studying and comparing normal and knockouts to assess the utility of MR Microscopy methods to distinguish gross and subtle phenotypic differences between them.

[1] J.W. Lichtman, Confocal Microscopy, Sci. Am., 271: 40-45, 1994.
[2] P.J. Basser et al, J Magn Reson, Series B, 103:247-254, 1994.
[3] S. Pajevic et al, 42:526-540, 1999.