AxCaliber – A Method to Measure the Axon Diameter Distribution and Density in Neuronal Tissues

Y. Assaf[1,2], T. Blumenfeld[1], G. Levin[1], Y. Yovel[1], P. J. Basser[3]

[1]Department of Neurobiochemistry, Tel Aviv University, Tel Aviv, Israel, [2]Functional Brain Imaging, Tel Aviv Sourasky Medical Center, Tel Aviv, Israel, [3]NICHD, National Institutes of Health, Bethesda, MD, United States

Introduction

Myeloarchitecture refers to different histological features, e.g., axonal density, myelin basic protein content, oligodendrocyte count and the axon diameter distribution, with which one can distinguish different white matter bundles. These parameters have been measured by histological methods but could not be quantified by conventional magnetic resonance imaging (MRI). The composite hindered and restricted model of diffusion (CHARMED) MRI framework can be used to measure at least two of these histological features: the axonal density (i.e., the volume fraction of the restricted compartment) and the axon diameter distribution[1-3]. In this work, we used cluster analysis of CHARMED-derived parameters to segment spinal cord fascicles. These clusters were compared to similar results obtained from histological staining.

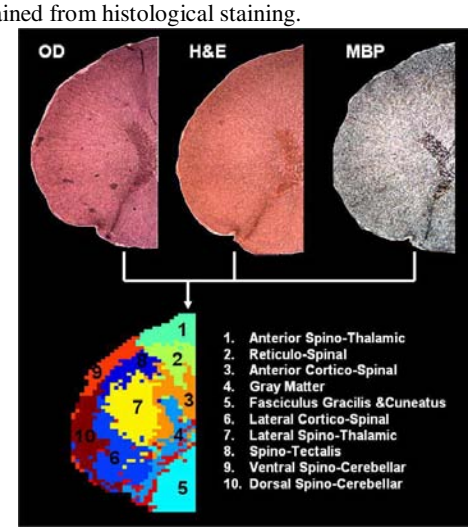

Methods

MR experiments were performed on a 7T scanner (Bruker, Germany) on fixed porcine spinal cords (n=5). High b-value diffusion weighted images (DWIs) were acquired with a stimulated echo DWI sequence with the following parameters: TR/TE=3000/166ms, δ=2.5ms, G_{max}=120 Gauss/cm, number of averages = 8, with the diffusion time, Δ, chosen from 20ms to 150ms in 8 increments. Diffusion gradients were applied only perpendicular to the nerve axis with 16 increments in gradient amplitude per diffusion time. The entire DW data set consisted of 128 spectra that were acquired in 51 minutes.

Following the MRI acquisition the spinal cords were assessed histologically. They were embedded in paraffin, sectioned into 10 microns slices, and stained with antibodies to myelin basic protein (MBP) and oligodendrocytes (OD), and with hematoxylin and eosin (H&E). Each stained slice was digitized and co-registered (using SPM2, UCL, London, UK). In-house software was used to segment these images and provide a statistical map containing distinct clusters (see example in Figure 1).

Analysis of MRI data was performed using an extension of the CHARMED framework described previously[3]. Within CHARMED we used a gamma-variate probability density function (PDF) to model the axon diameter PDF (ADPFD). Parameters of the gamma distribution were then fit using the entire MRI data set. The measured signal decay was assumed to be a sum of DW signal decays for each axon diameter weighted by its respective area-weighted probability. The DW signal decay for each axon was calculated using the formula of van Gelderen et al.[4] describing restricted diffusion in cylinders.

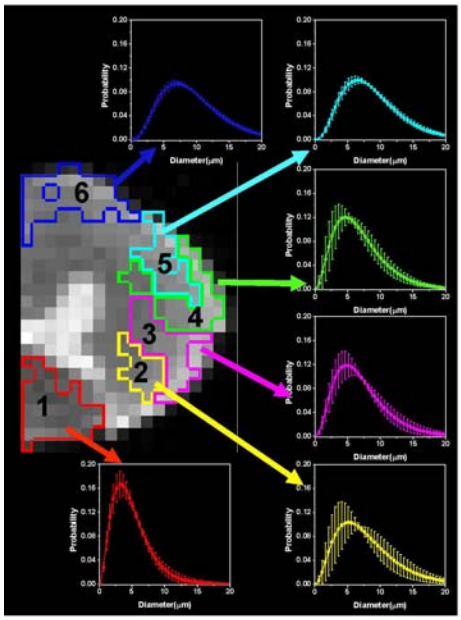

Results

Histology – Histological analyses of a spinal cord using OD, H&E and MBP staining are shown at the top of Figure 1. Using cluster analysis of these images, we were able to identify 10 areas having distinct myelo- and cyto-architecture. These areas are shown in Figure 1 and include the cortico-spinal and spino-thalamic tracts, among others.

MRI – Imaging data fit to CHARMED yielded two parameters of the gamma function in each voxel as well as the volume fractions of the restricted and hindered compartments. The k-means algorithm was used to perform cluster analysis on the map of these four estimated quantities. The algorithm extracted 6 clusters with a distinct axon diameter distribution, as shown in Figure 2. The six regions found by cluster analysis of CHARMED parameters are similar to regions found in the histological analysis. The corresponding regions are given in the Table below.

Discussion and Conclusions

For a high b-value DWI data set with different diffusion times, we used the CHARMED analysis framework to resolve the axon diameter distribution of different white matter areas within the porcine spinal cord. Strong homology is seen between areas found by CHARMED and those found by myelo- and cyto-architecture analysis. This MRI methodology may have potential applications for anatomical/morphological studies in development, degeneration, disease and trauma to the CNS and PNS. Of particular interest is the potential use of this approach in the assessment of white matter structure in various diseases (e.g., ALS and autism) and during spinal cord regeneration.

Figure 1	Figure 2	Area
Area #1	Area #6	Anterior spino-thalamic tract
Area #8	Area #5	Spino-tectalis tract
Area #9	Area #4	Ventral spino-cerebellar
Area #10	Area #3	Dorsal spino-cerebellar
Area #6	Area #2	Lateral cortico-spinal
Area #5	Area #1	Fasciculus gracillis & cuneatus

References

(1) Assaf Y, Freidlin RZ, Rohde GK, Basser PJ. Magn Reson Med 2004; 52:965-78. (2) Assaf Y, Basser PJ. Neuroimage. 2005; 27:48-58.. (3) Assaf Y, Basser PJ. Proc. Int. Soc. Magn. Reson. Med. 2005;13:741. (4) van Gelderen P, DesPres D, van Zijl PCM, Moonen CTW. J Magn Reson B 1994; 103:255-260.